

CASE SPOTLIGHT

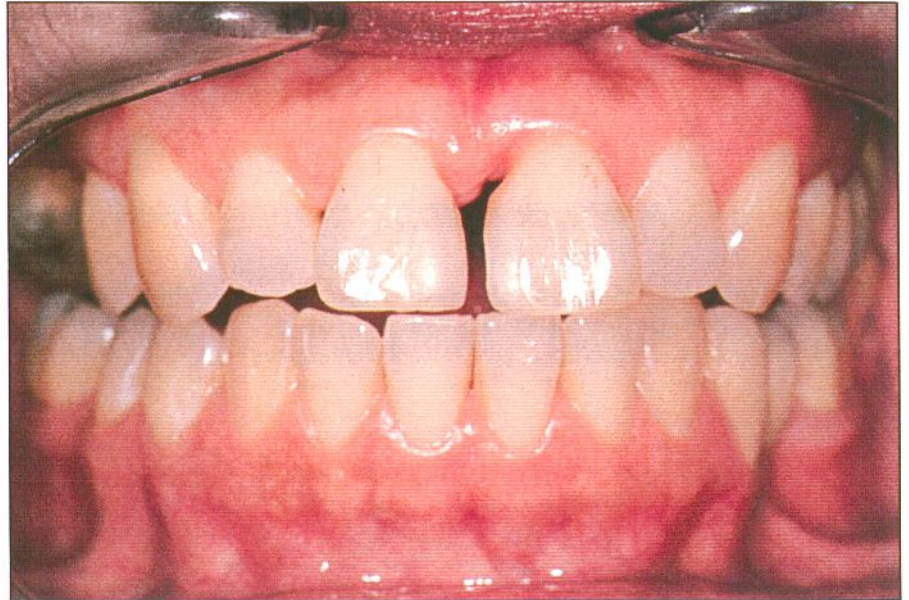
"This female patient presented with a large diastema between 8 and 9 (partially filled in with an old anterior composite restoration). Due to her history of periodontal problems, she was also suffering from gum recession in the anterior and had lost a number of teeth in the posterior. Needless to say, she was very unhappy with her smile.

The biggest primary concern was how to close the large space between her anterior teeth while providing a natural-looking overall smile. Orthodontics was briefly considered as part of the treatment plan but quickly rejected due to the size of the space. On a whole mouth basis, the question of whether to use all-ceramic restorations entirely or a mix of all-ceramic and PFM was considered. It was decided to use a combination of restorations to meet her unique needs in each area of her mouth. These were presented through a Diagnostic wax-up prepared by Aurum Ceramic.

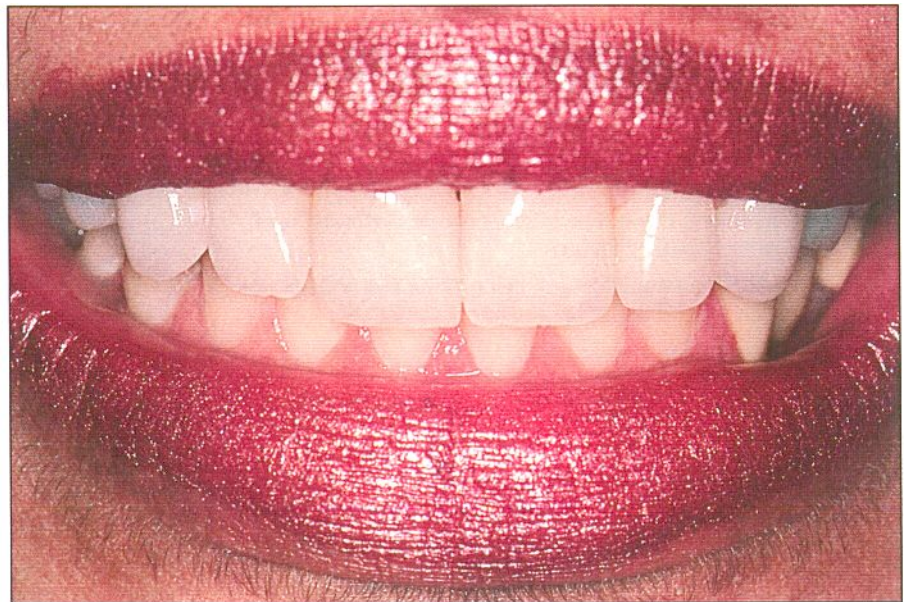Seven IPS Empress veneers (teeth 5 through 11) were placed to close her diastema and give her smile symmetry. Significant root contouring was required on 8 and 9 to make the restorations appear as if they were emerging naturally from the gingival tissue. In the posterior, a four-unit Princess pressable ceramic on metal bridge was placed from 12 to 15 to provide strength and 360° ceramic margins for esthetics. Teeth 2 through 4 were restored using a IPS Empress reinforced with Vectris bridge. The result was an entirely new smile. The patient was ecstatic with the final esthetic and functional results."

Dr. Jeff L. Rodgers

Restorations fabricated by
Aurum Ceramic.



Large diastema between 8 and 9, gum recession.



Restored Smile.

Jeff Rodgers, D.D.S., graduated from the University of Alabama School of Dentistry in 1995. After working as an Associate for five years, he set up his own practice specializing in cosmetic and restorative dentistry on January 1, 2000. A member of the AACD, Dr.

Rodgers is a past graduate of the Las Vegas Institute's Advanced Anterior, Comprehensive (Masters) and Occlusion I programs. He plans to attend LVI's Occlusion II and Full Mouth Reconstruction programs in July.